

Rapid Radiology with new updates.

Work flow

Website: <https://apps.rapidrad.com/login/>

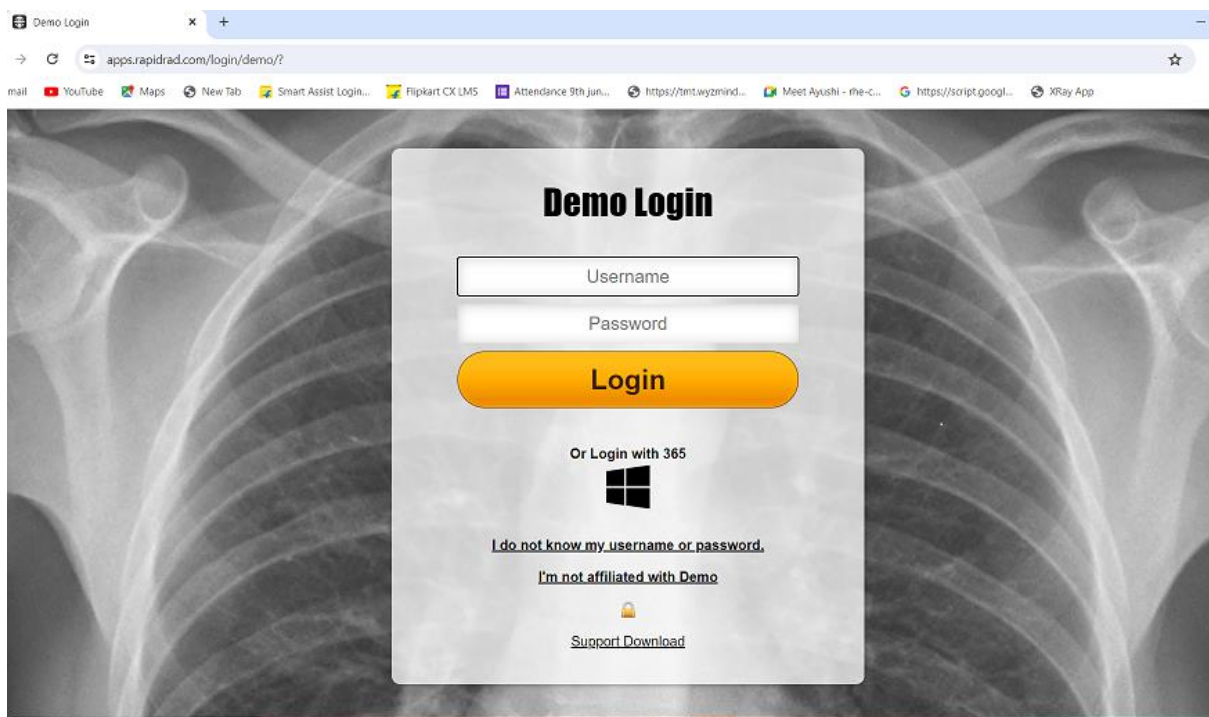
user id: imam

pass: trad4321

Note: We can open this Rapid on Google chrome.

First open the Rapid website on Google chrome.

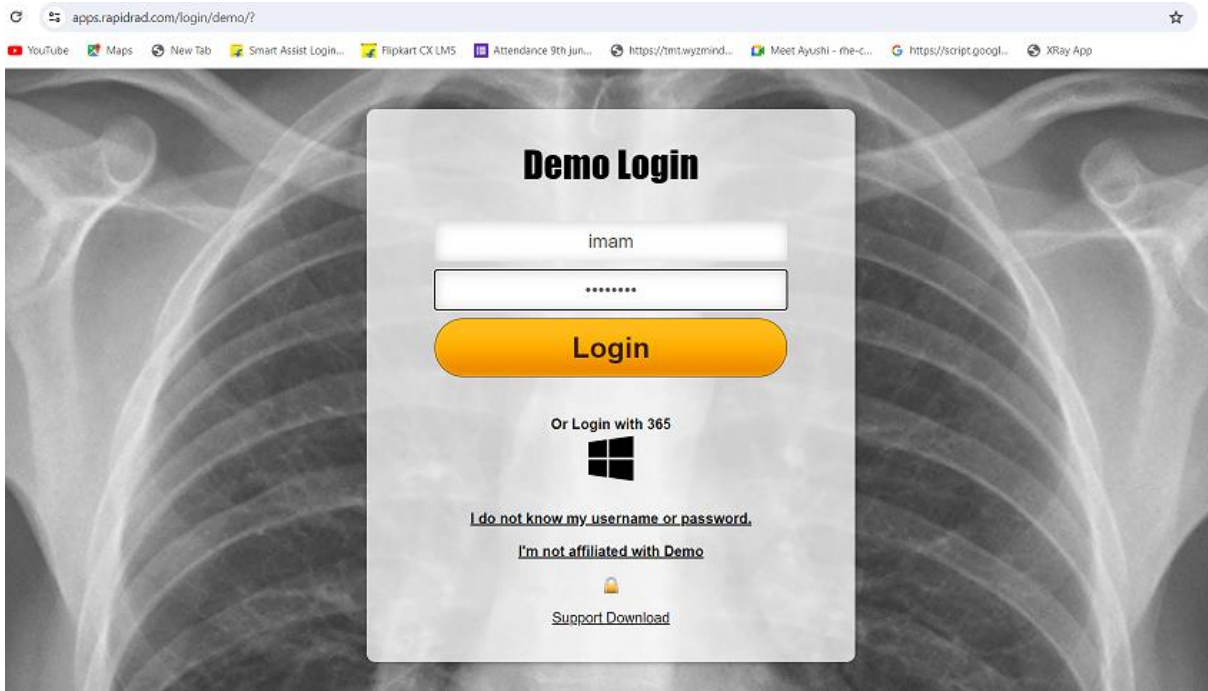
Website: <https://apps.rapidrad.com/login/>



Login with appropriate username and password.

user id: imam

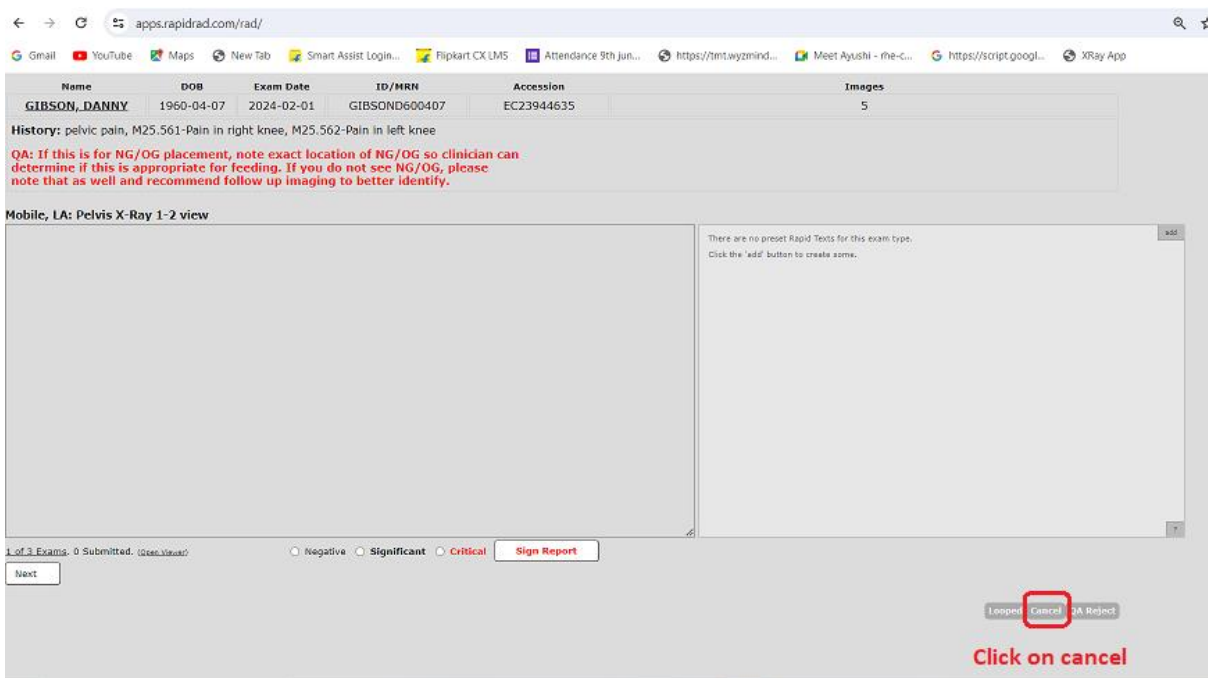
pass: trad4321



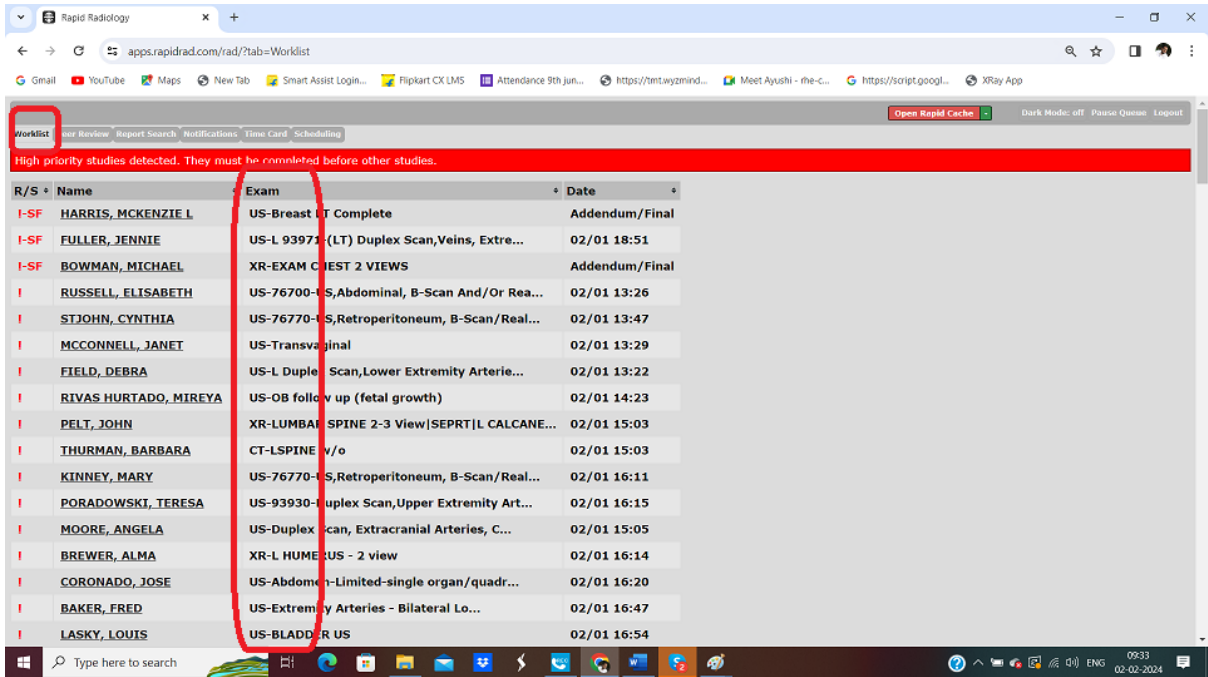
Then click on Login.

Once login done,

By default, some others existing case will get open, cancel it by clicking on cancel button.

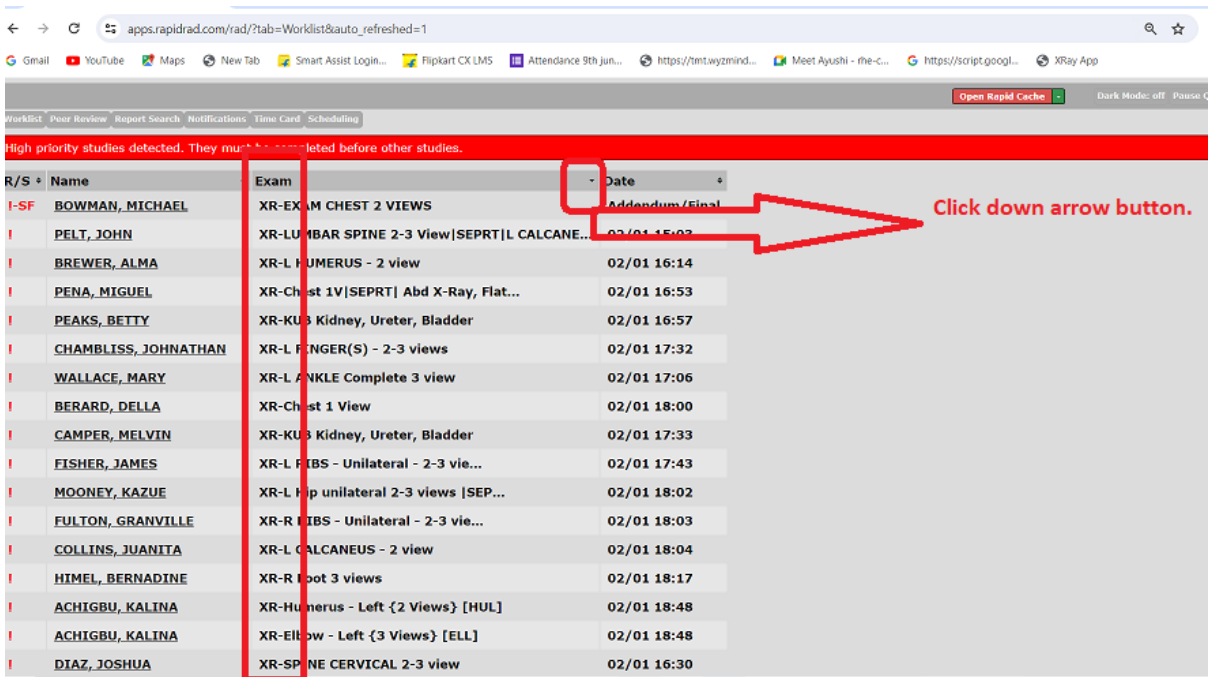


Now we can see the home screen of the Rapid, and worklist with different modalities, like US, CT and X-rays.



To sort the Exam in proper categorisation, click on the down arrow button.

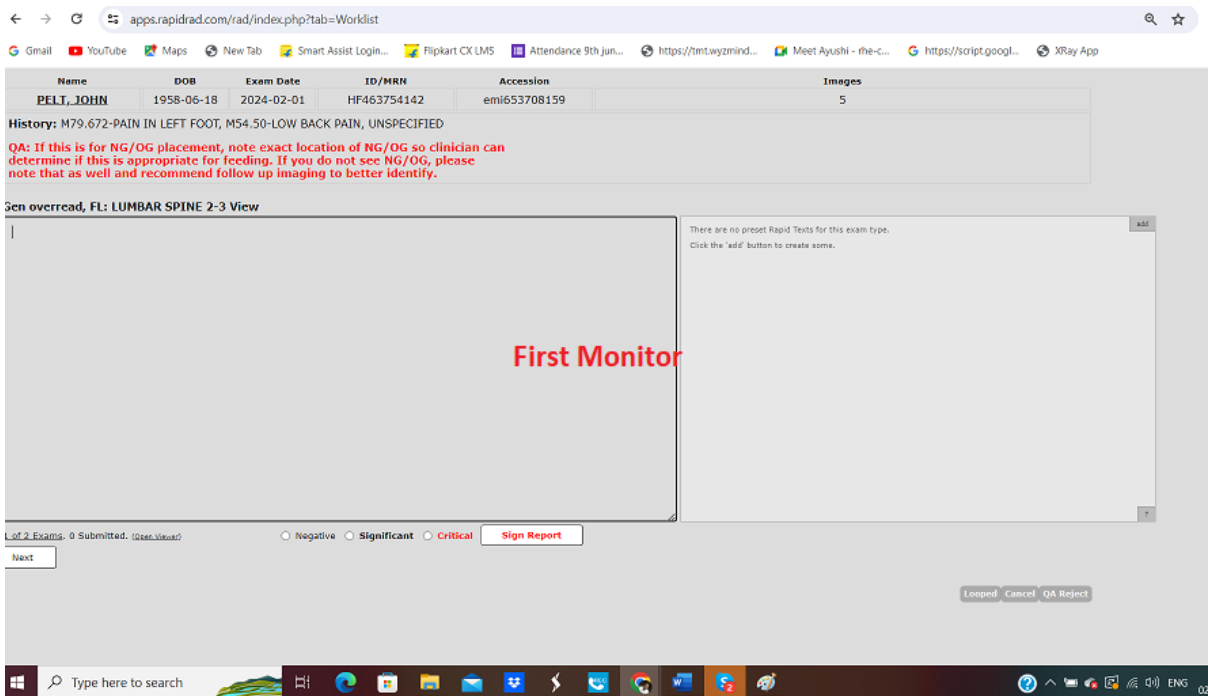
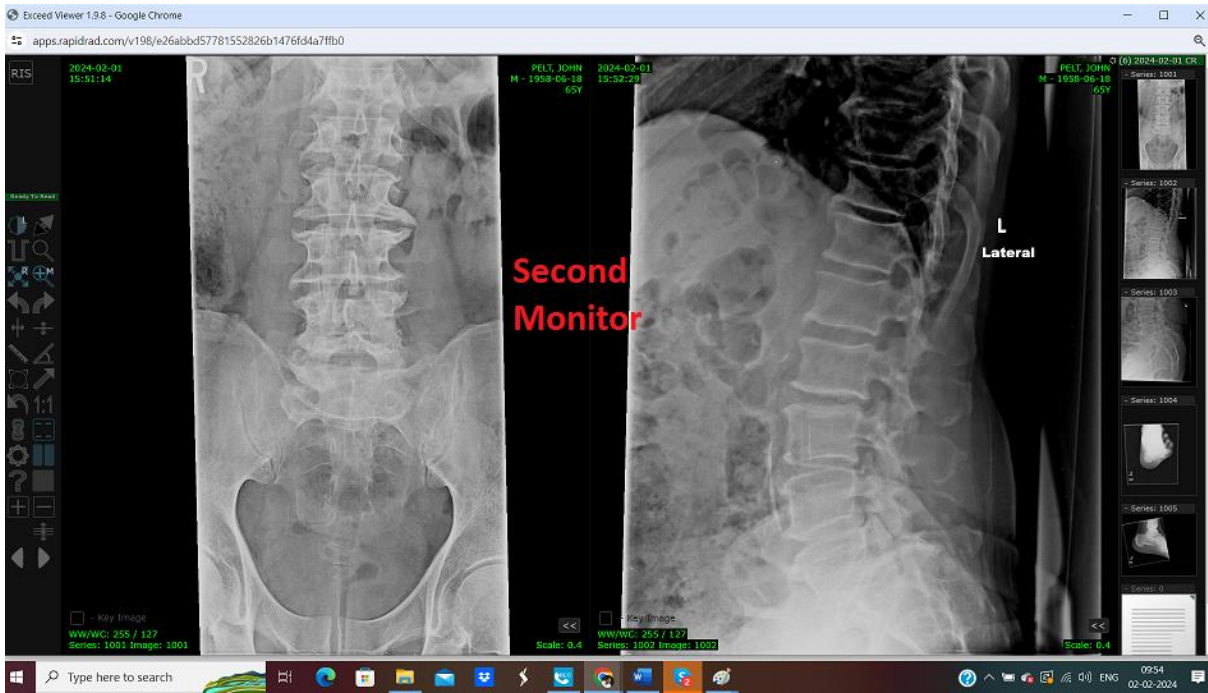
Now we can see all the X-rays in list.



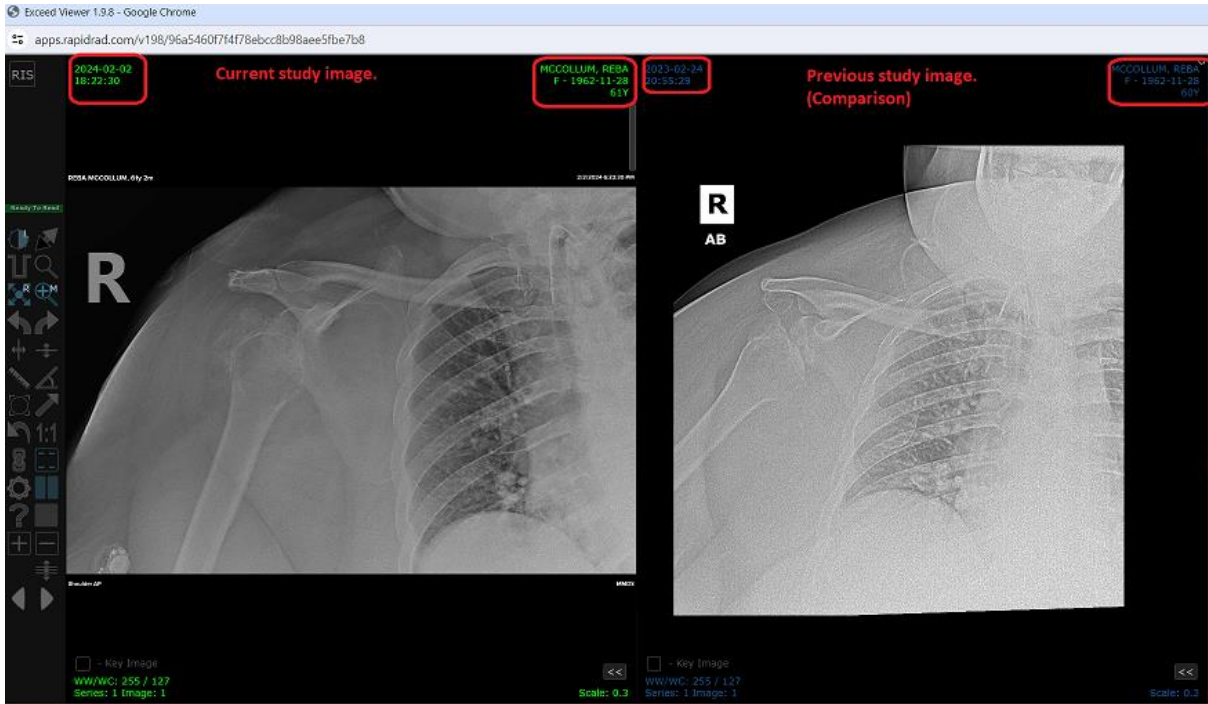
To open a case, click on that Name of the patient from the list.

Images and report will get open at a time.

Drag the images on second monitor.

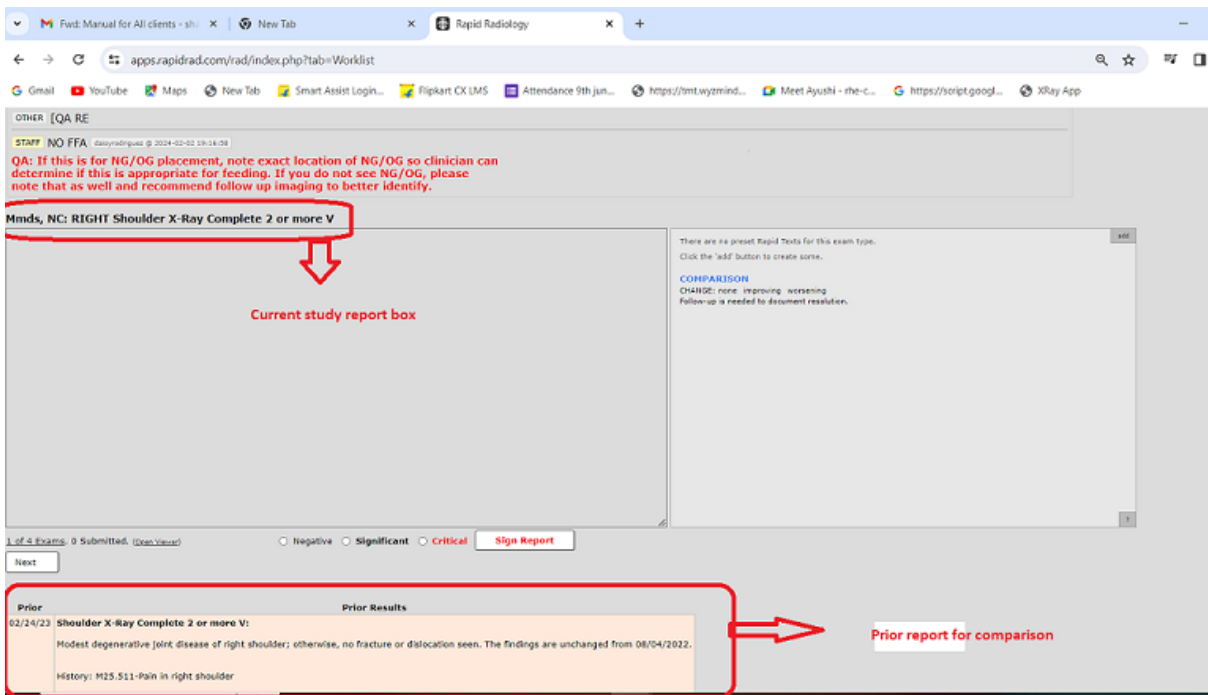


We can see the patient Name, age and current and previous study images, in the second Monitor.

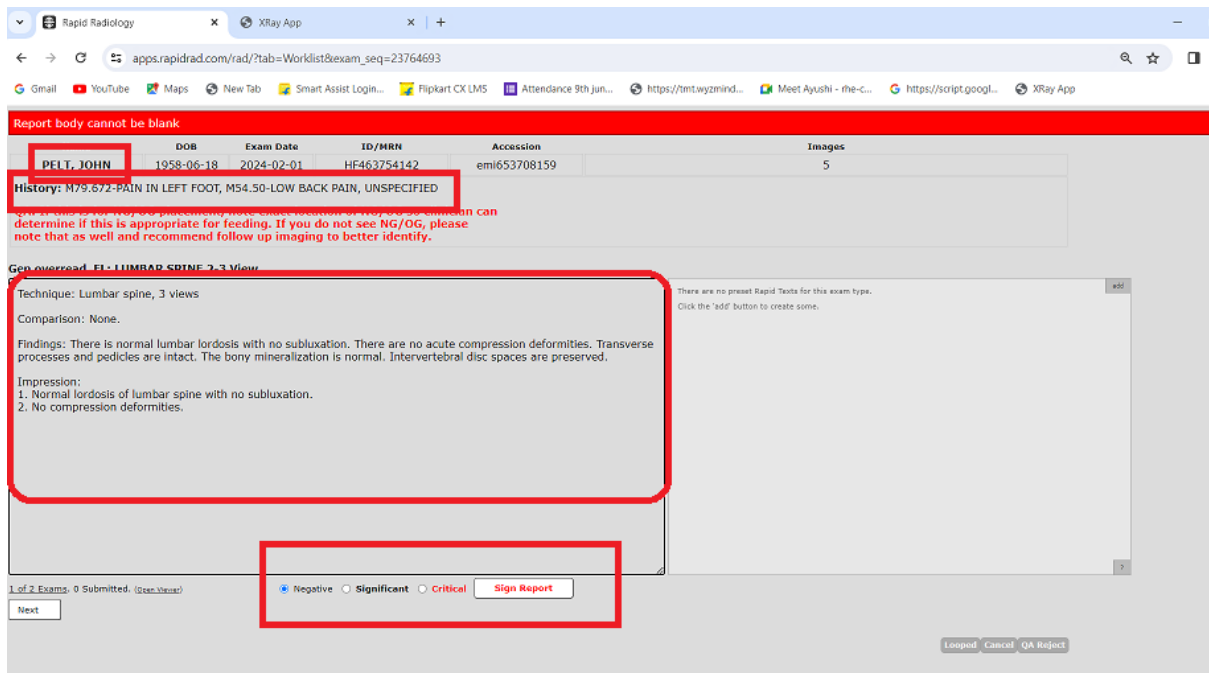


Note: Only if prior study image is available then only, we can see the previous images.

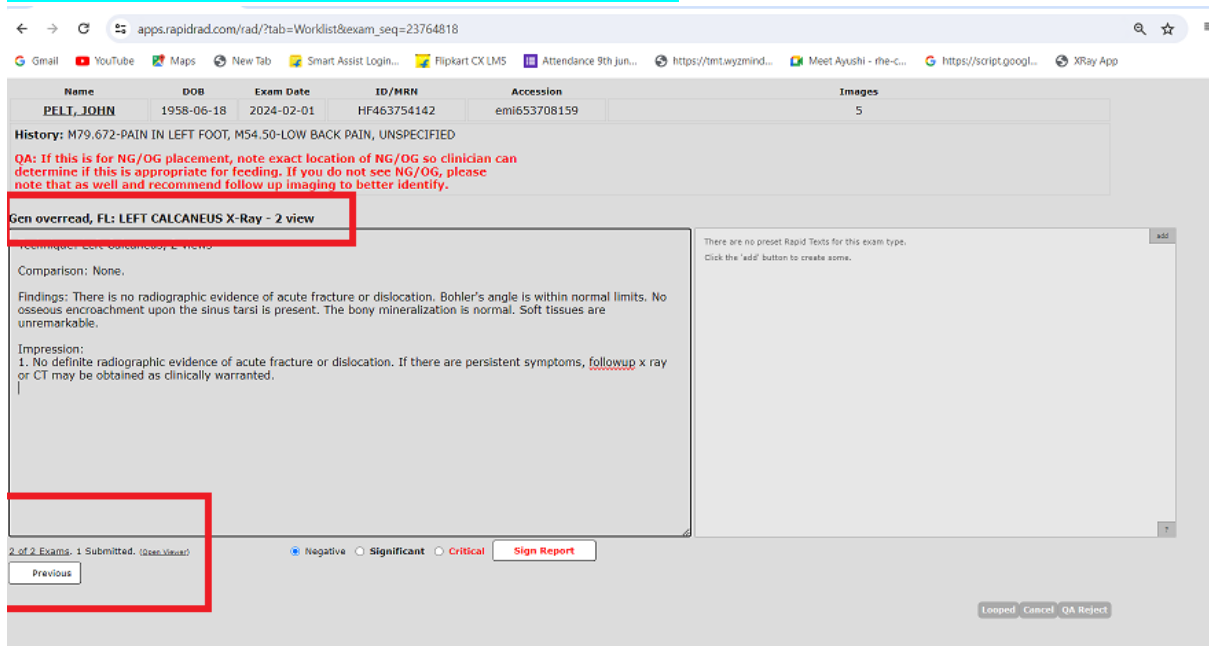
And similar We can see the patient Name and current study history, along with previous study reports in the first Monitor if available.



Note: Only if prior study report is available then only, we can see the previous study reports.



If the same patient has multiple studies, we can check the same from the list of exams, click on the next option to go with second case and follow the same.



If we have 2 studies, then study count will be 2.

If we have only one study, then study count will be 1.

After opening the report – Follow the 7 steps.

The most important steps need to be followed in process are:

1. Name matches with the name on Images.
2. Order (study) matches with Images.
3. Laterality (Right/left) matches with markers (R/L) on images.
4. Comparison.
5. History/Client comments of patient.
6. Age of patient (Old/middle/young age).
7. Read the report before signing off.

Report body cannot be blank

DOB	Exam Date	ID/MRN	Accession	Images
PELT, JOHN 1958-06-18	2024-02-01	HF463754142	eml653708159	5

History: M79.672-PAIN IN LEFT FOOT, M54.50-LOW BACK PAIN, UNSPECIFIED

Gen overread: **FL - LUMBAR SPINE 2-3** View

Technique: Lumbar spine, 3 views

Comparison: None.

Findings: There is normal lumbar lordosis with no subluxation. There are no acute compression deformities. Transverse processes and pedicles are intact. The bony mineralization is normal. Intervertebral disc spaces are preserved.

Impression:

1. Normal lordosis of lumbar spine with no subluxation.
2. No compression deformities.

1 of 2 Exams: 0 Submitted. (See View)

Negative Significant Critical

Next

Looped Cancel QA Reject

Once got the dictation from the doctor, paste the report in first monitor by selecting appropriate option given. (i.e.) Negative, significant or critical and sign the report.

Thankyou!